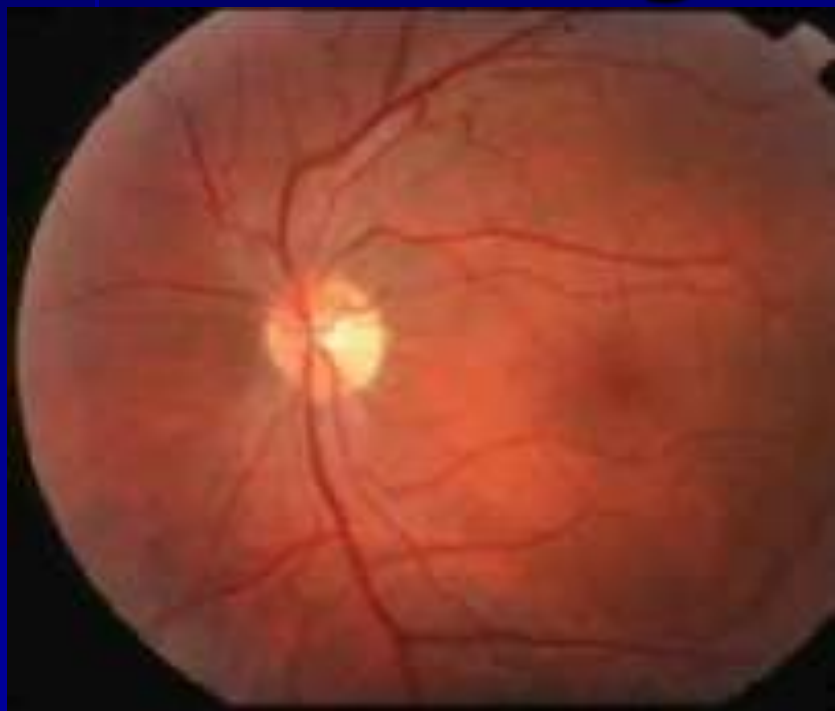


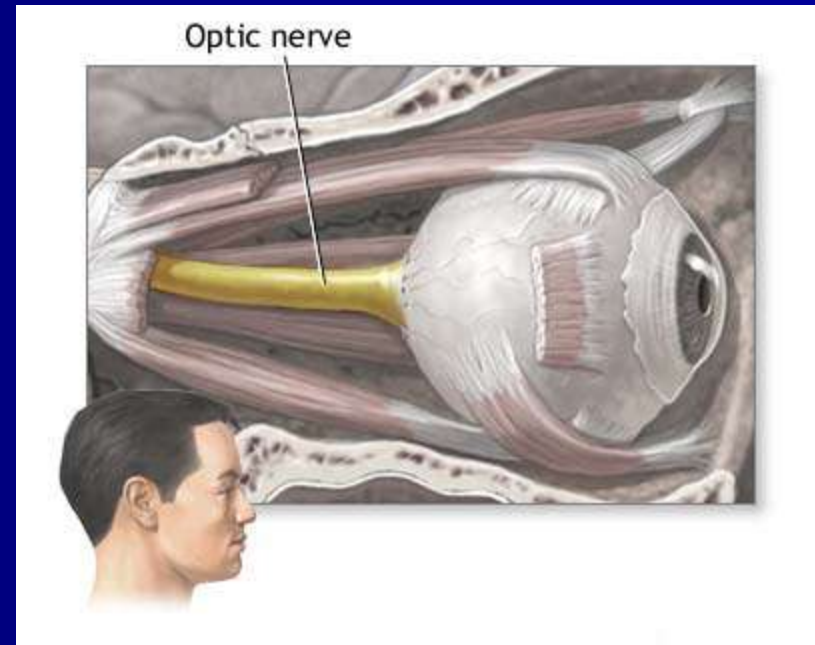
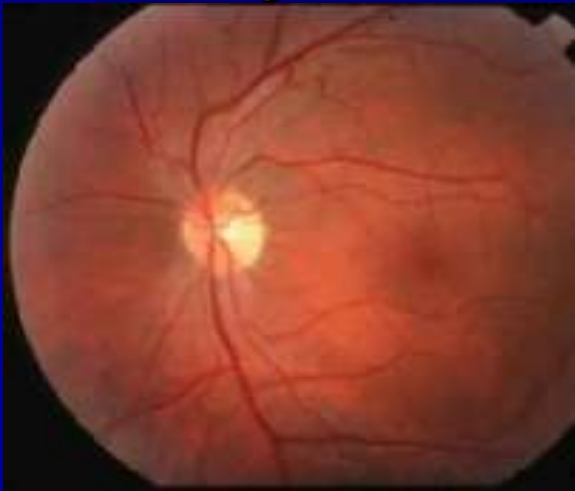
Vidni živac

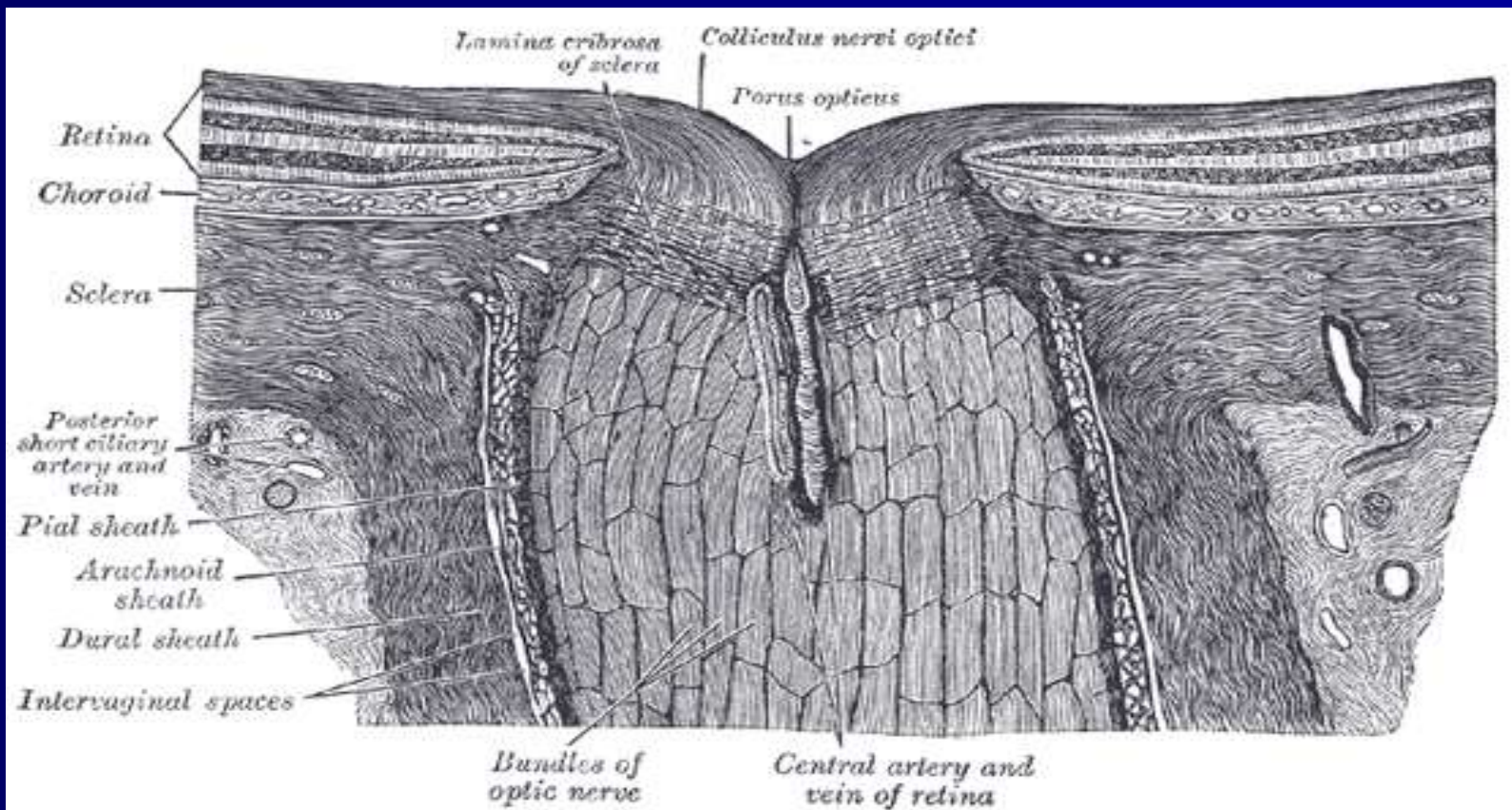
Prof.dr Dragan Veselinović



Vidni živac-N.Opticus

- Predstavlja istureni deo mozga
- II neuron vudnog puta, čiji aksoni (1.200.000 aksona)
- Omotači-dura mater,archnoidea,pia mater).
- Intrabulbarni deo- Papilla n.optici-optic disc
- Retrobulbar-orbitalni-pars orbitalis
- Intrakanacularni
- Intrakranijalni deo



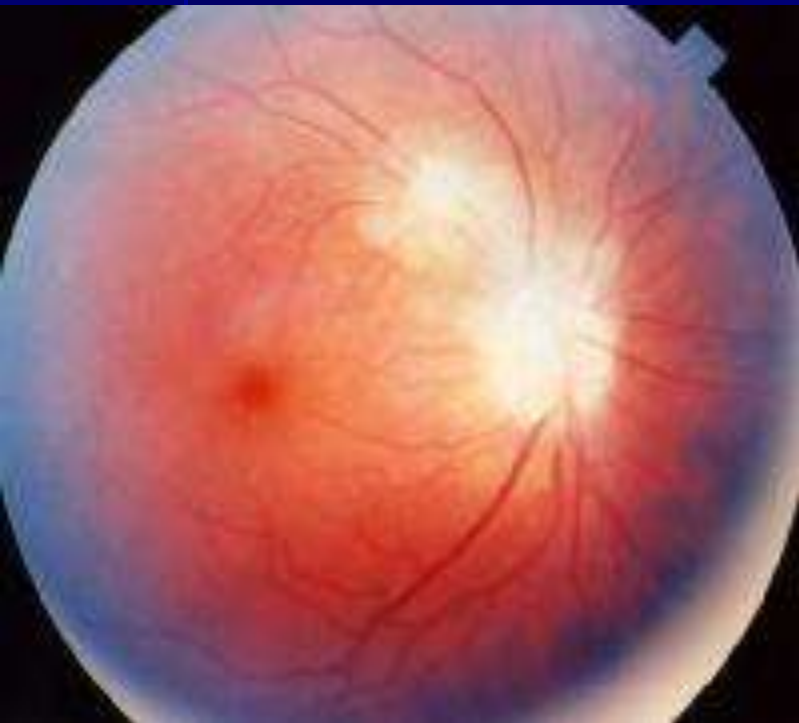

Neuritis n.optici

- Papillitis
- Neuritis retrobulbaris
- Neuritis optohiasmatica

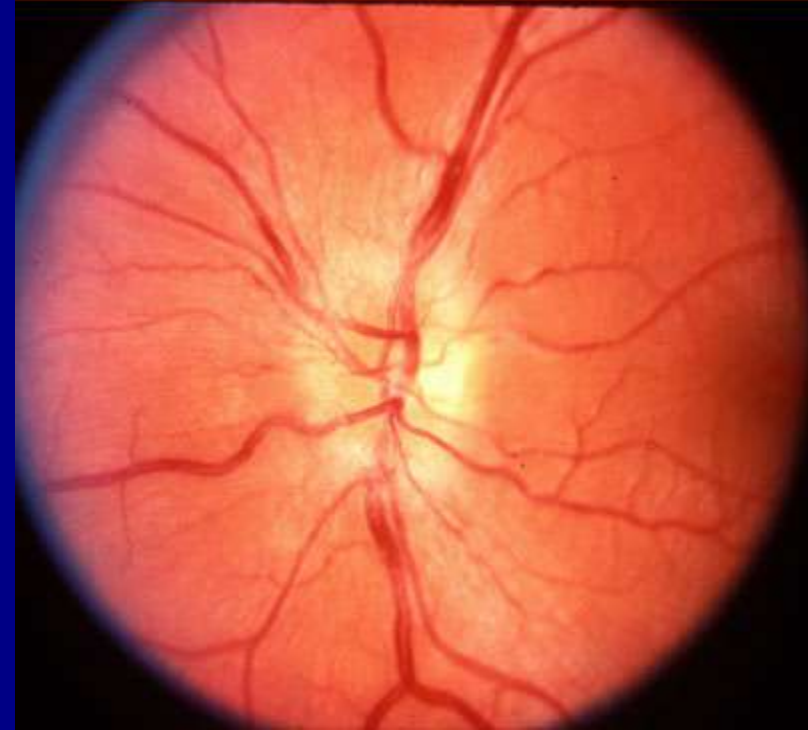
Papillitis

- Zapaljenje prednjeg dela vidnog živca-vidi se oftalmoskopskim pregledom.
- A) Papila može biti zahvaćena zapaljenjem iz okoline
- B) U okviru sistemskih bolesti, fokalne infekcije.



Medscape®

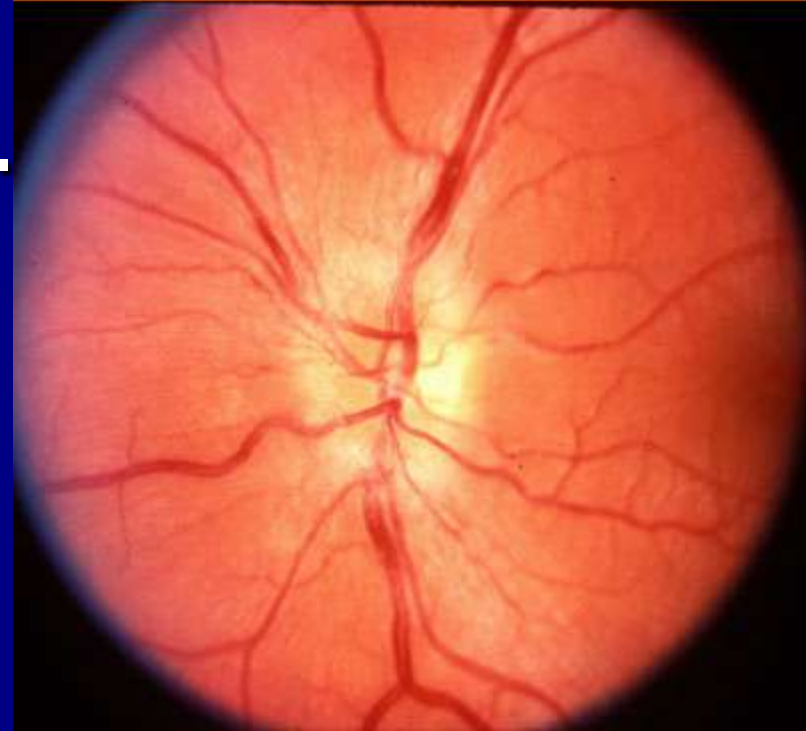
www.medscape.com

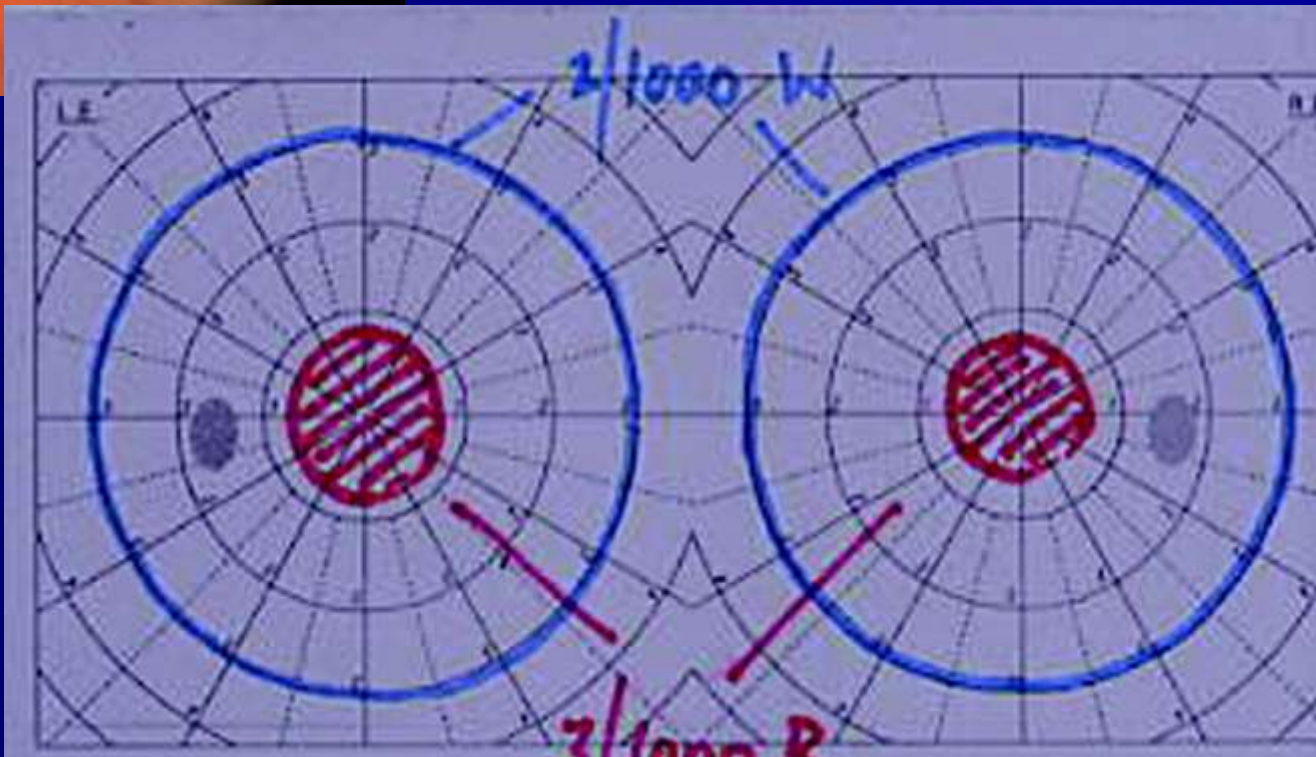
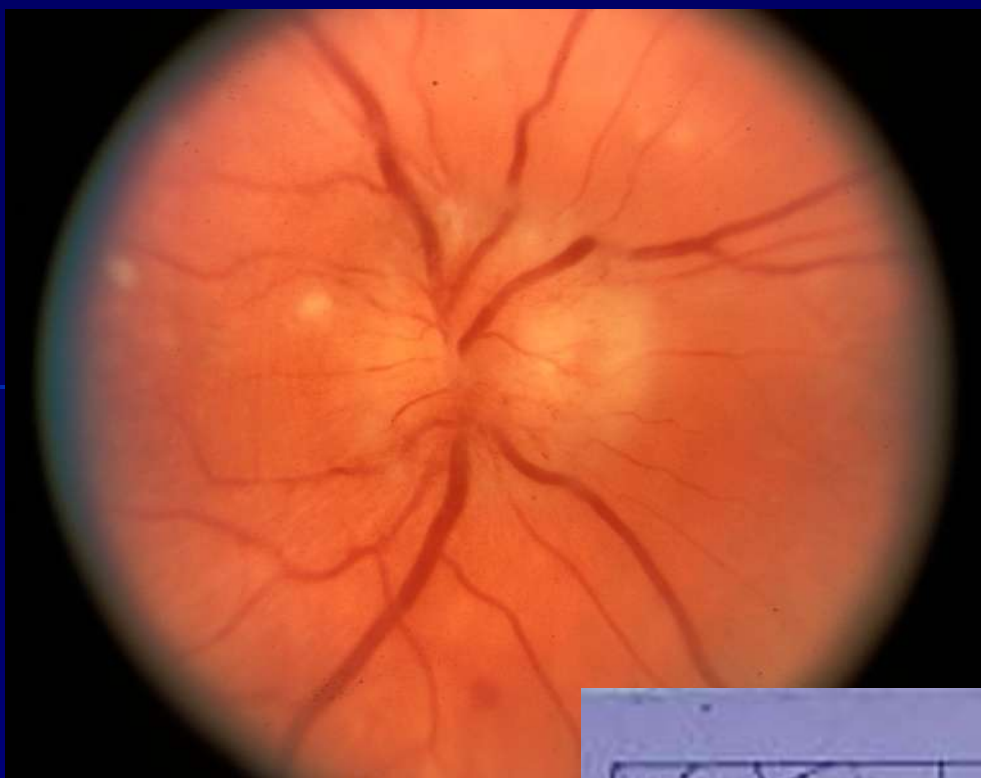

- Pacijen se žali na smanjenje vida
- Nastaje centralni skotom
- Poremećaj u kolornom vidu
- Papila vidnog živca hiperemična
- Edematozna
- Nejasne granice
- Prominencija ne prelazi 3D.

Medscape®

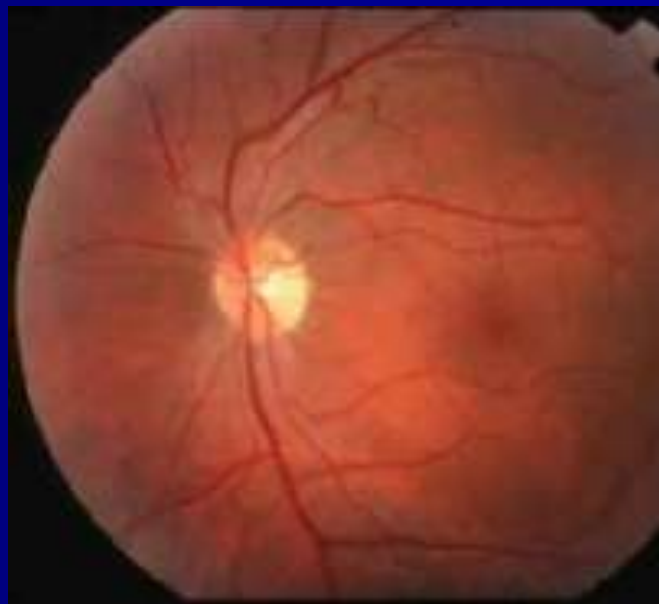www.medscape.com





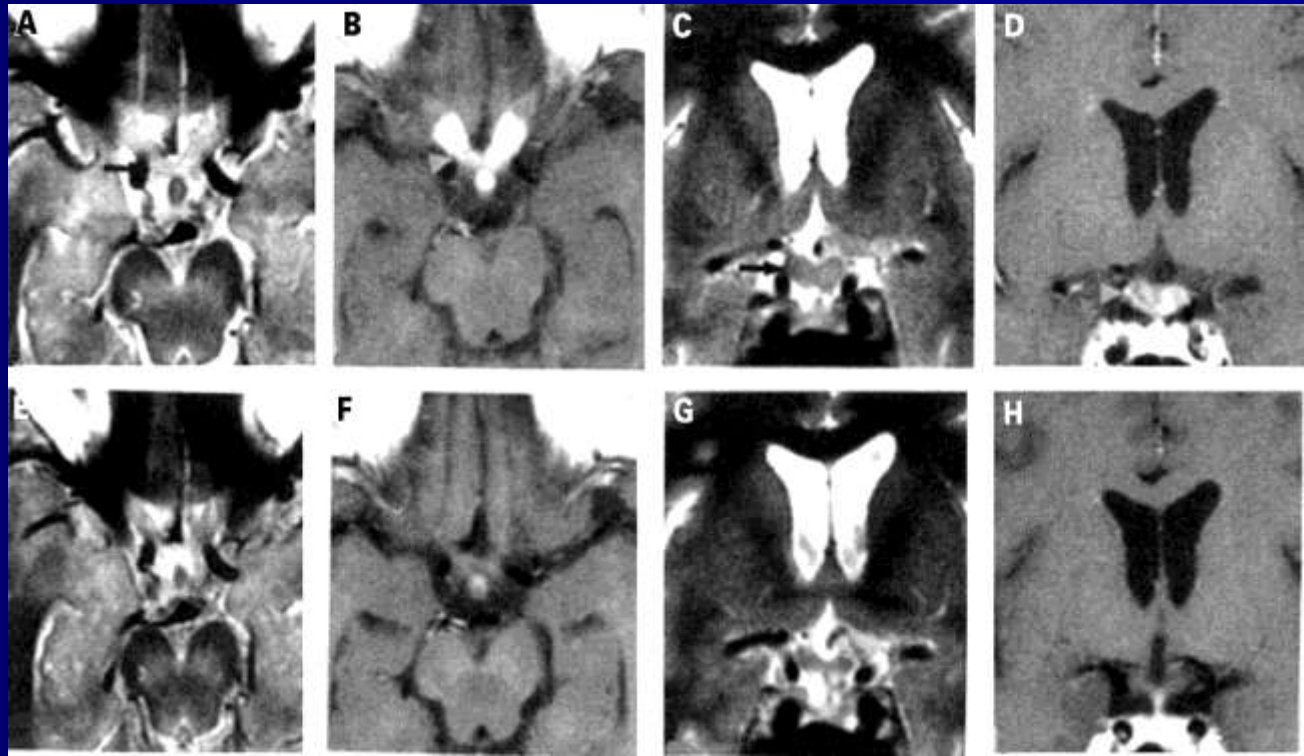
Neuritis retrobulbaris

- Zapaljenje iza očnog bulbusa.
- “pacijent se žali da ne vidi, ali i doktor ne vidi nikakvne promene na očnom dnu, nalaz je normalan”



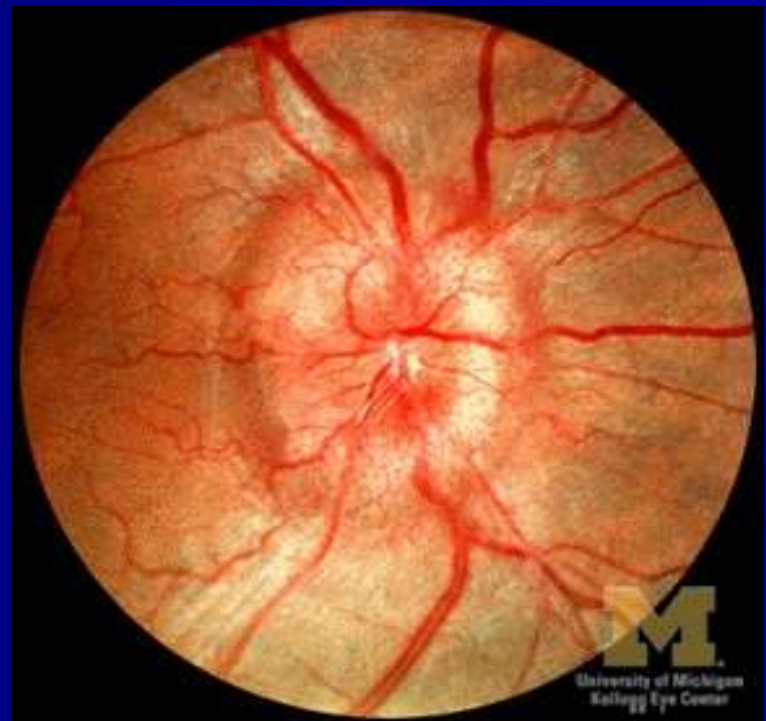
Neuritis optohiasmatica

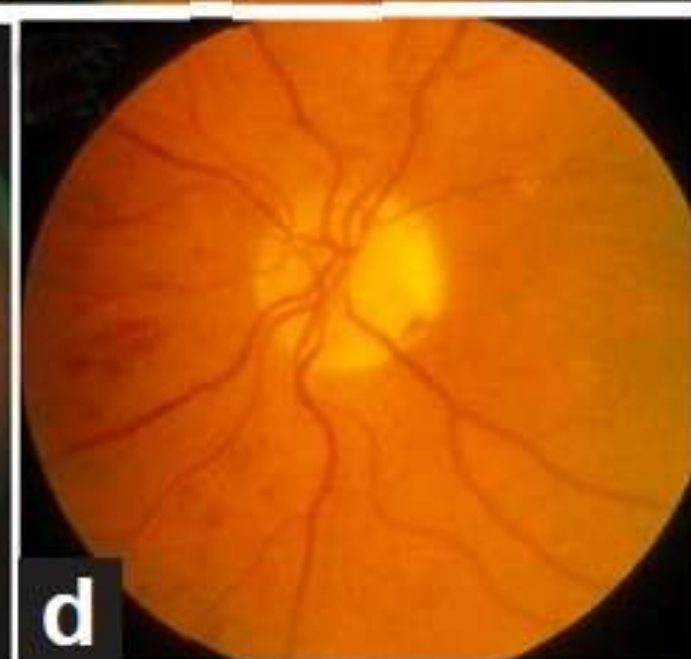
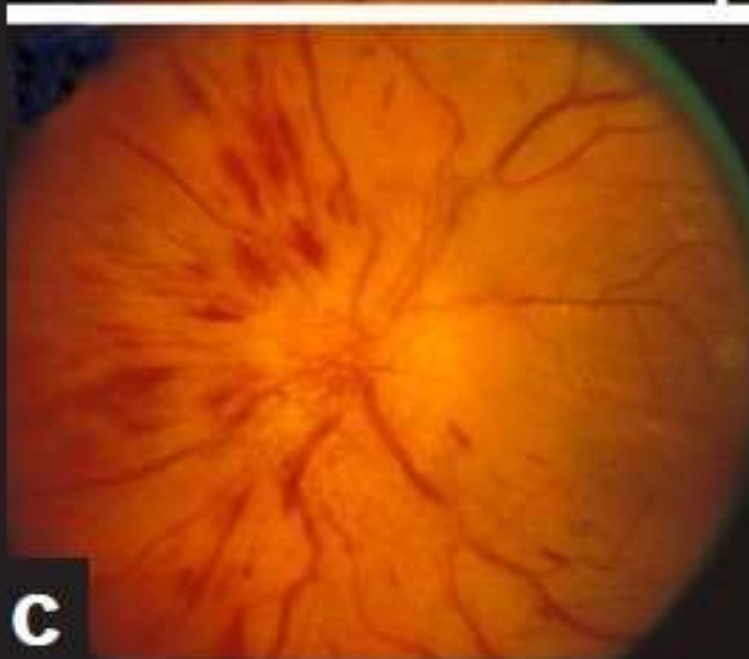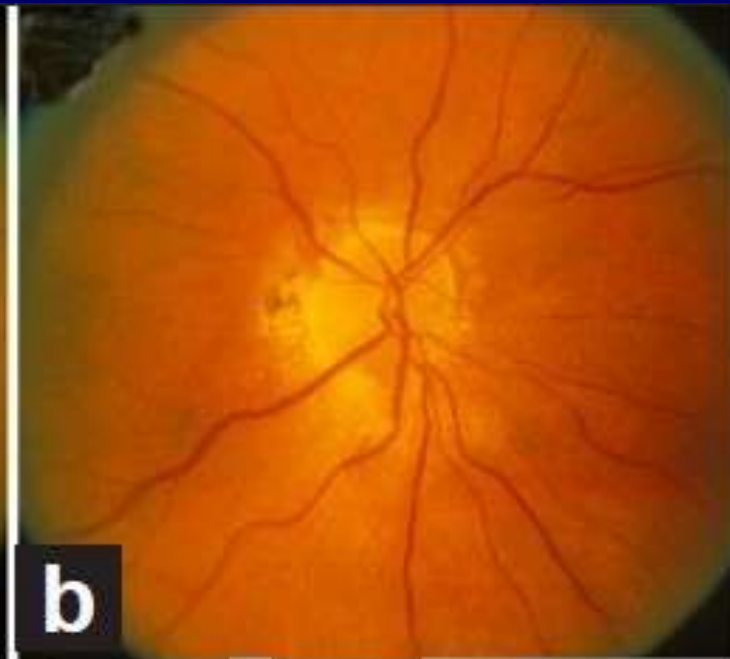
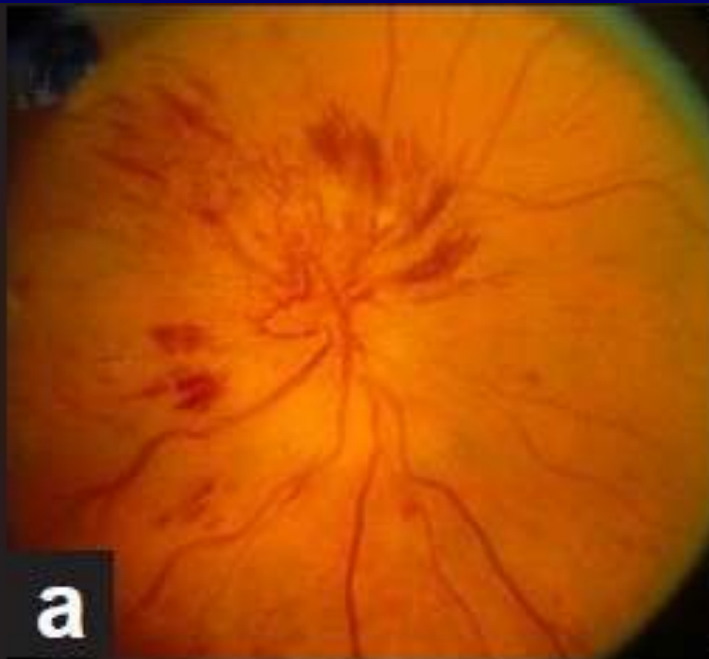- Zapaljenje na nivou hijazme
- Trauma
- Virusi



Stasis papillae n.optici

- Simptom povećanog intrakranijalog pritiska
 - Tu
 - Aneurizme
 - Povrede
 - Zapaljenja





Atrofija vidnog živca-atrohio n.optici

- Posledica različitih oboljenja

